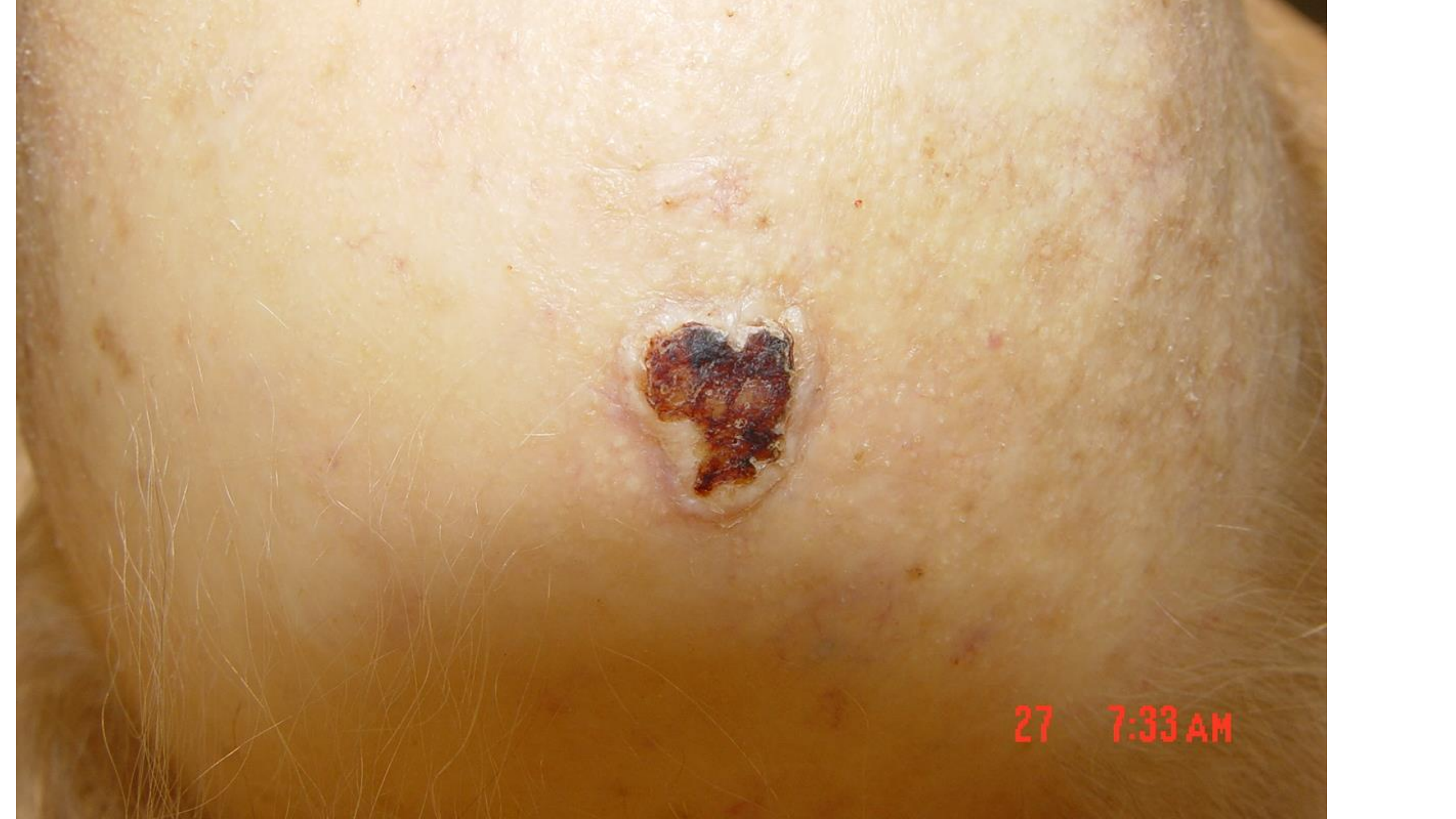

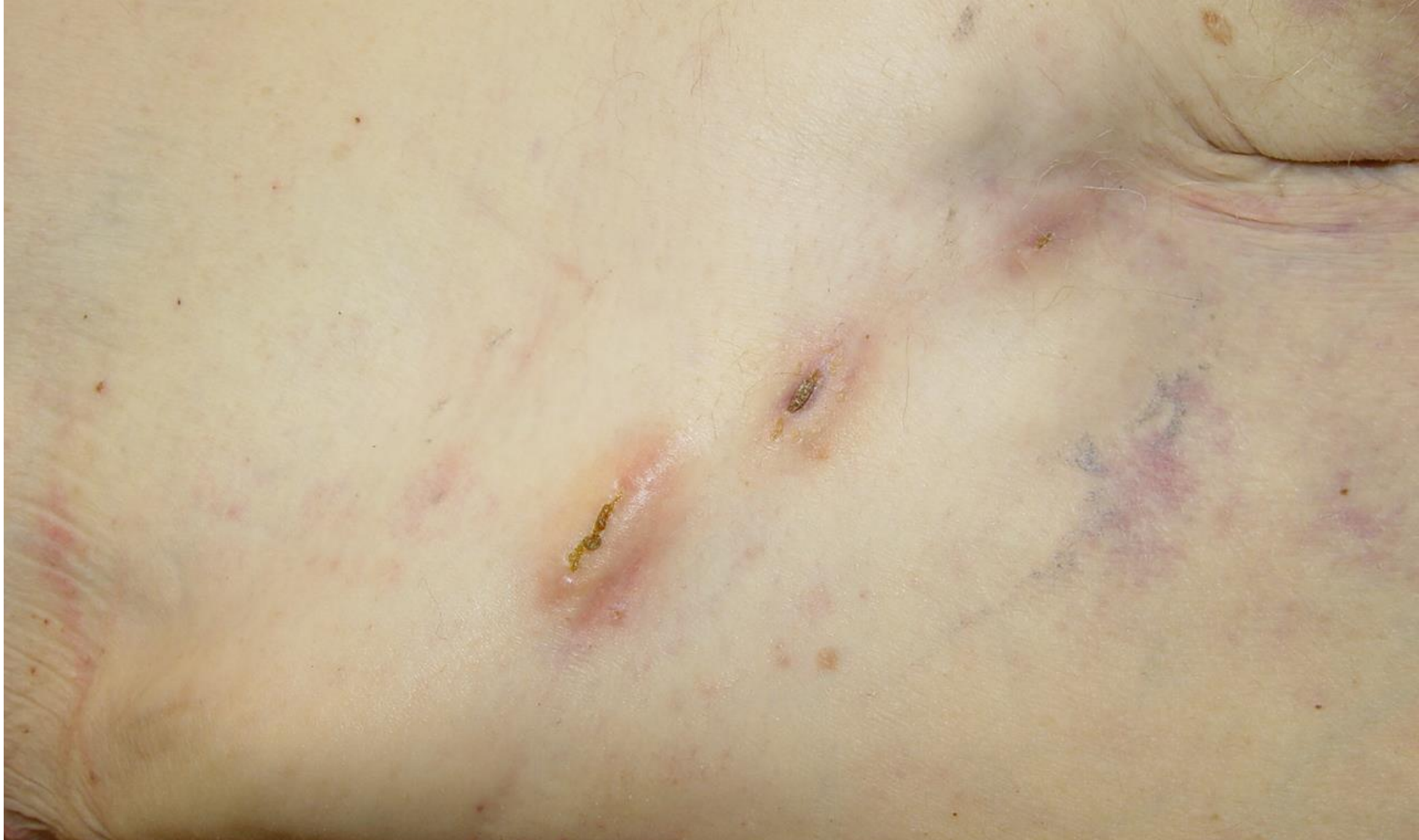Verkäsende inguinale Lymphknoten-Tuberkulose

Z. n. Therapie Falldemonstration männlich 68 Jahre alt

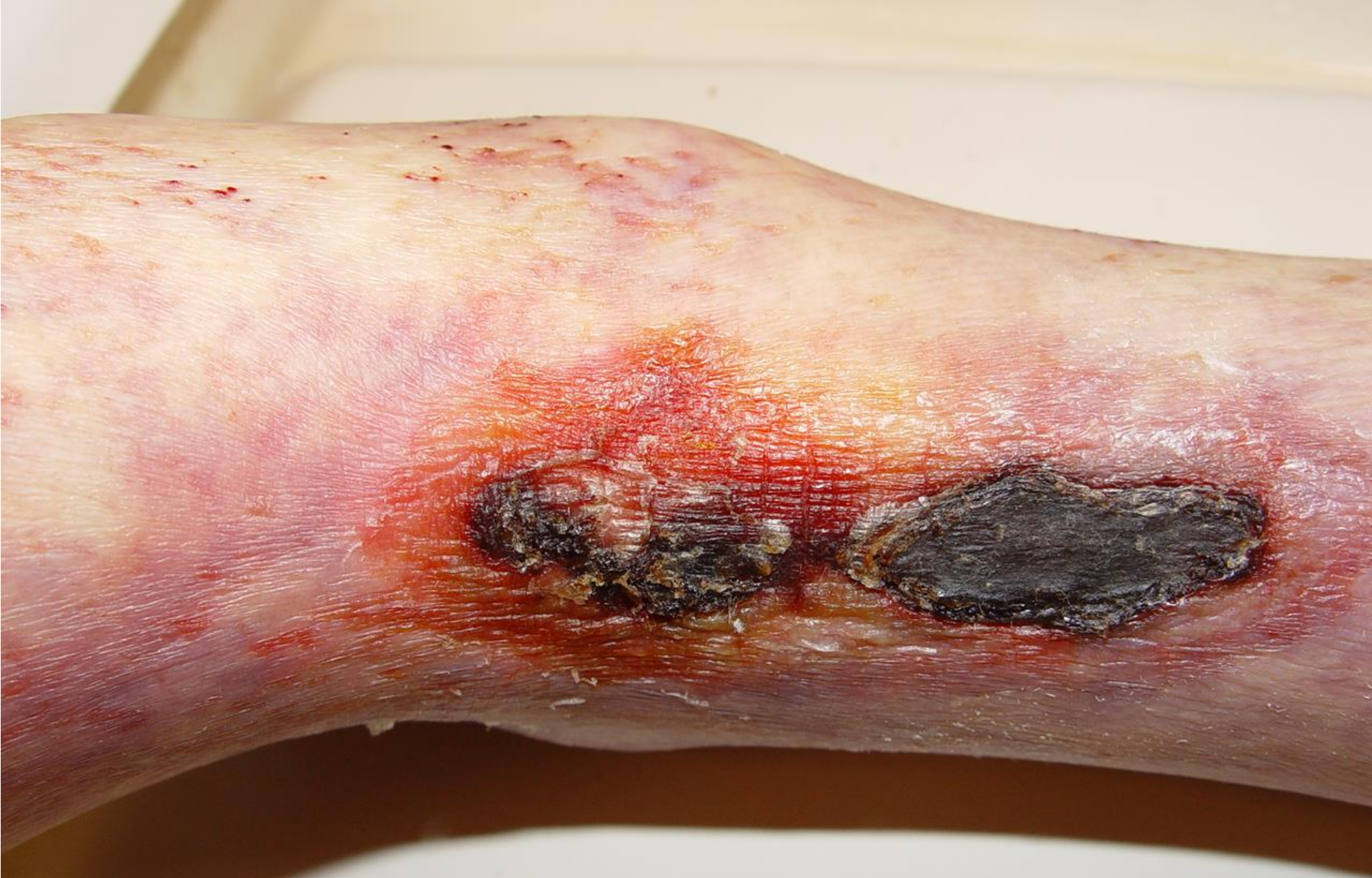1. Verkäsende inguinale Lymphknoten-Tbk. Z.n.Therapie
2. Essentieller dekompensierter Hypertonus
3. Chronischer Alkoholismus
4. Allg. Atherosklerose
5. Todesursache : hochgradiges akutes Lungenödem bei leukozytärer Herdpneumonie, dekompensierter Leberzirrhose, Z.n. therapierter LK-Tbk und Koronarinsuffizienz



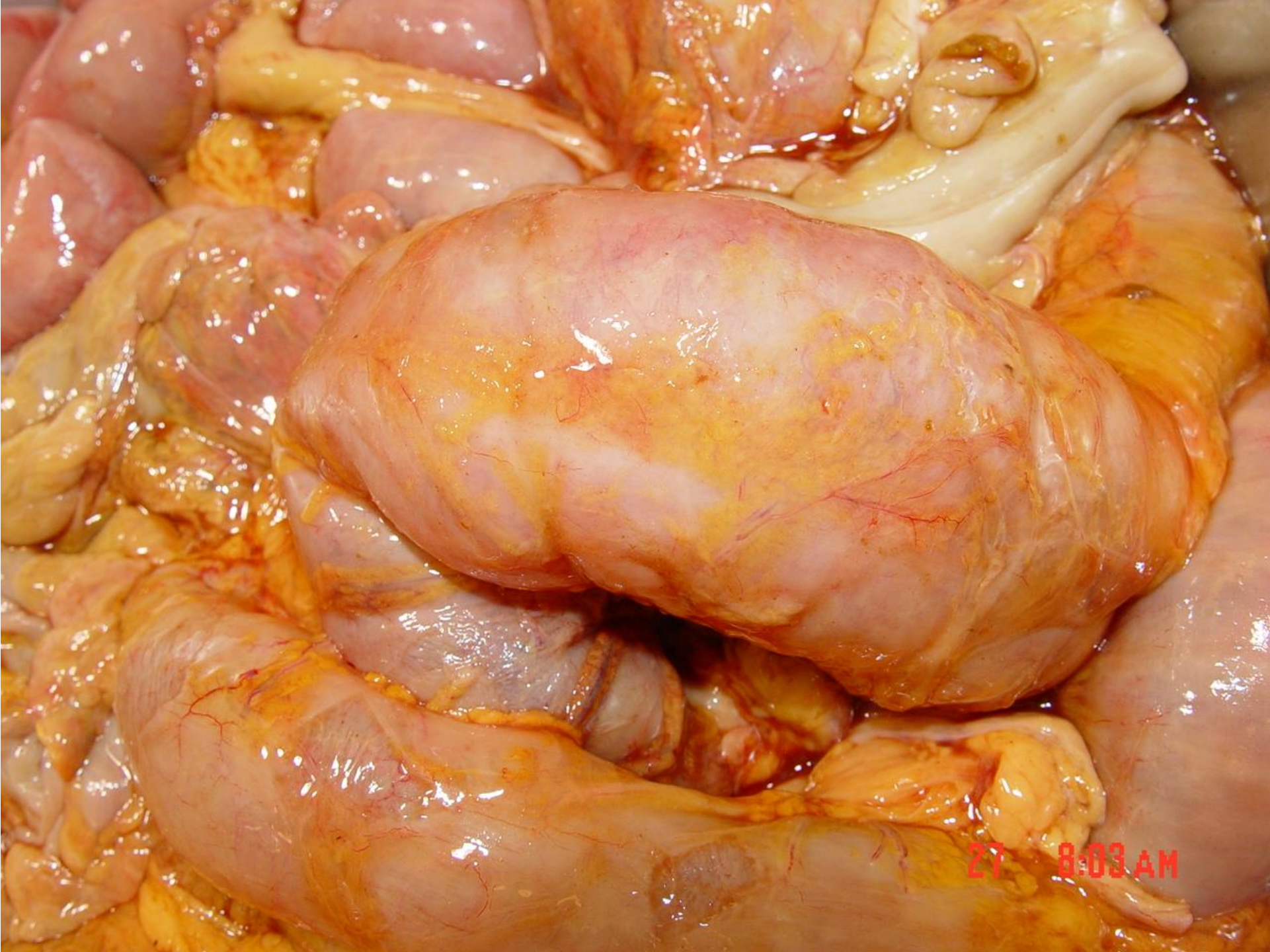
27 7:33 AM



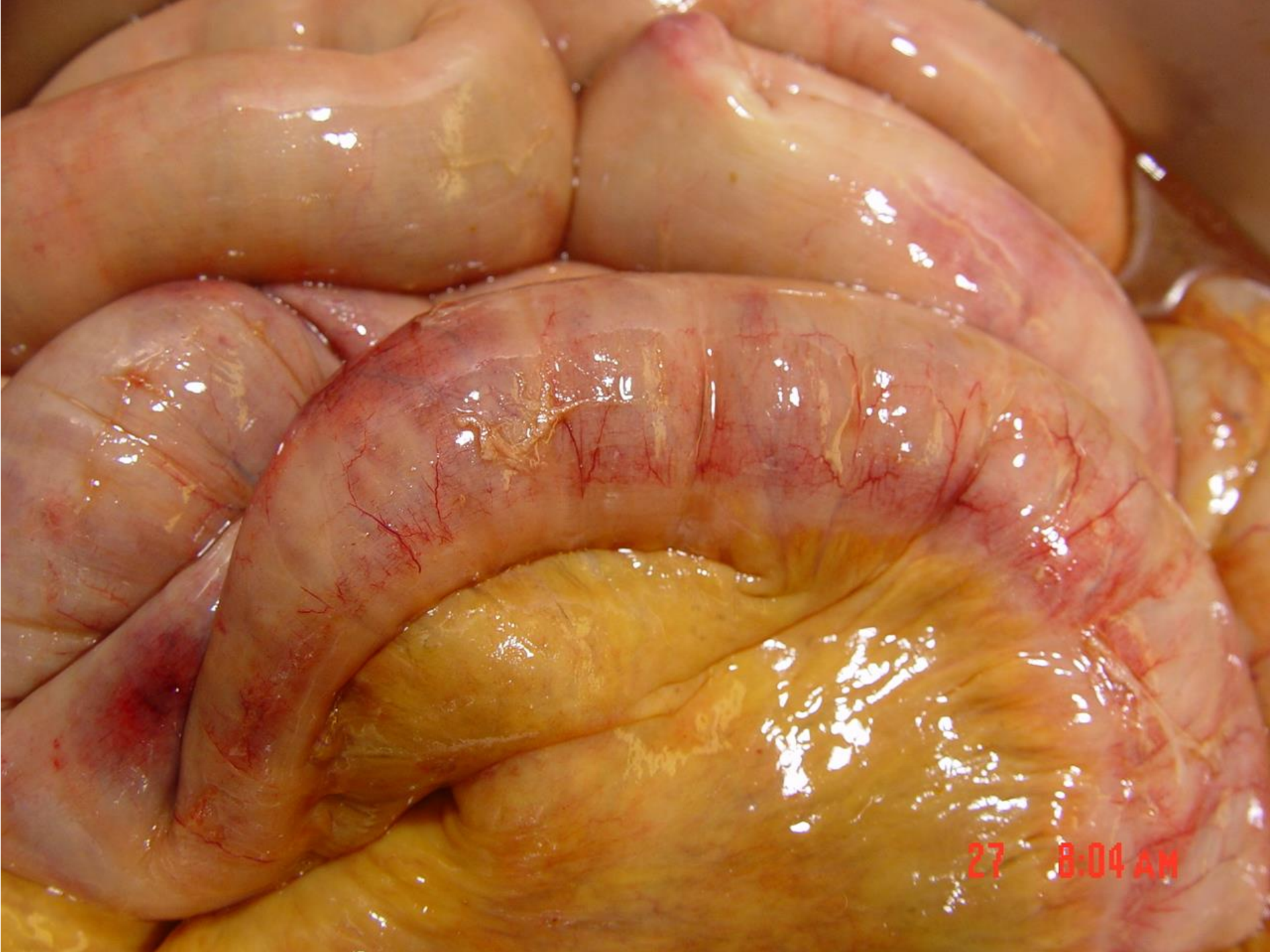27 7:33 AM



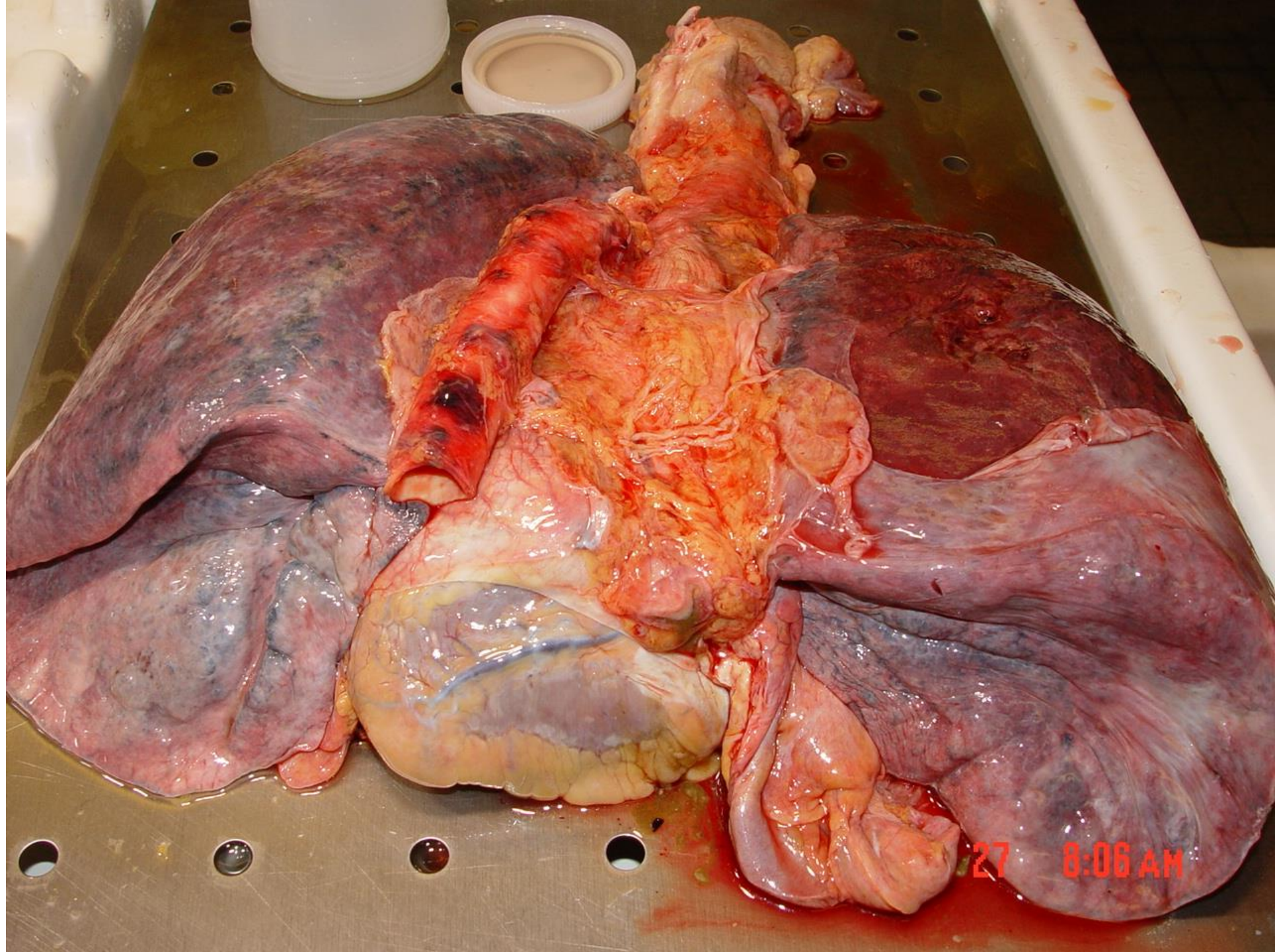
27 7:34 AM

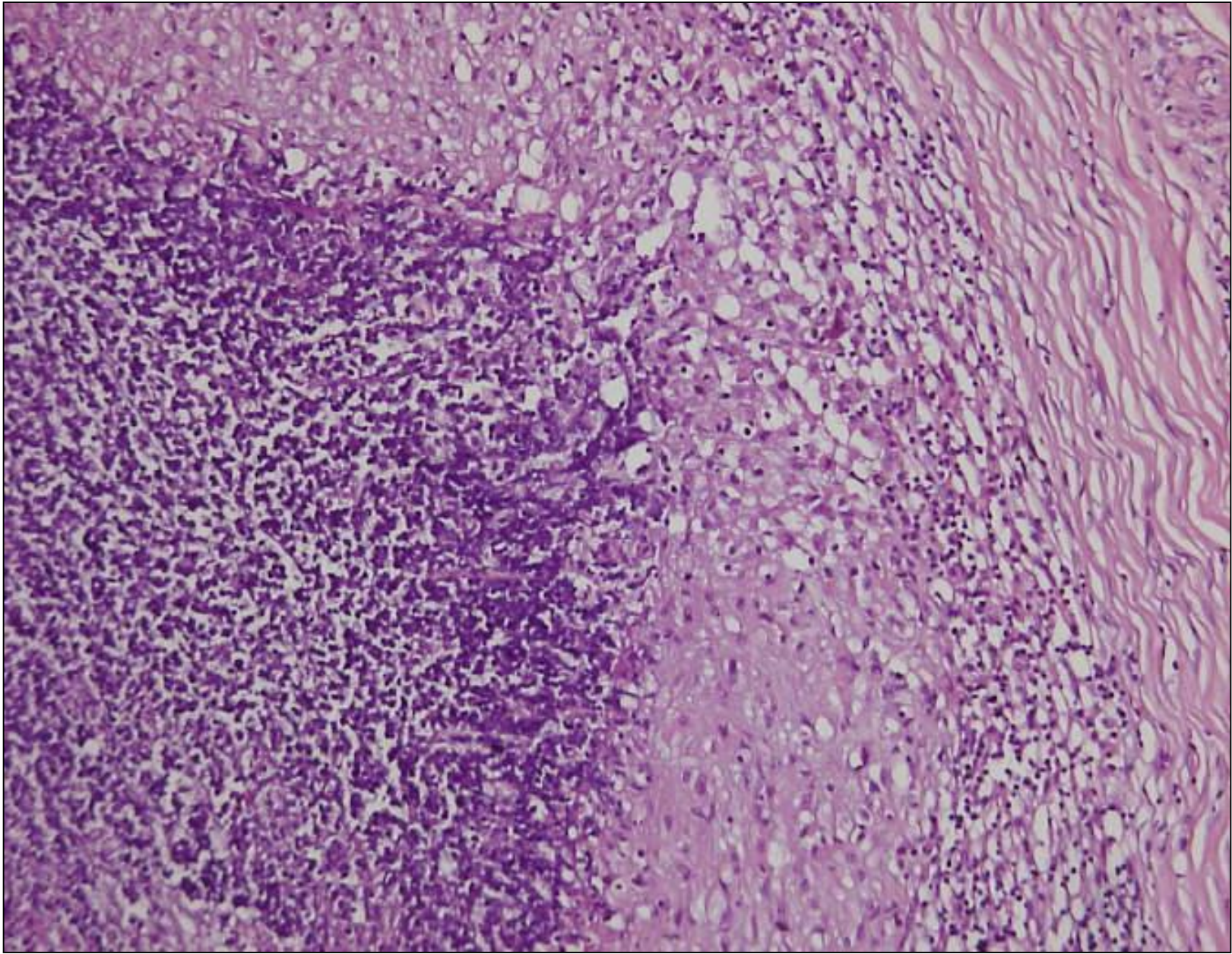


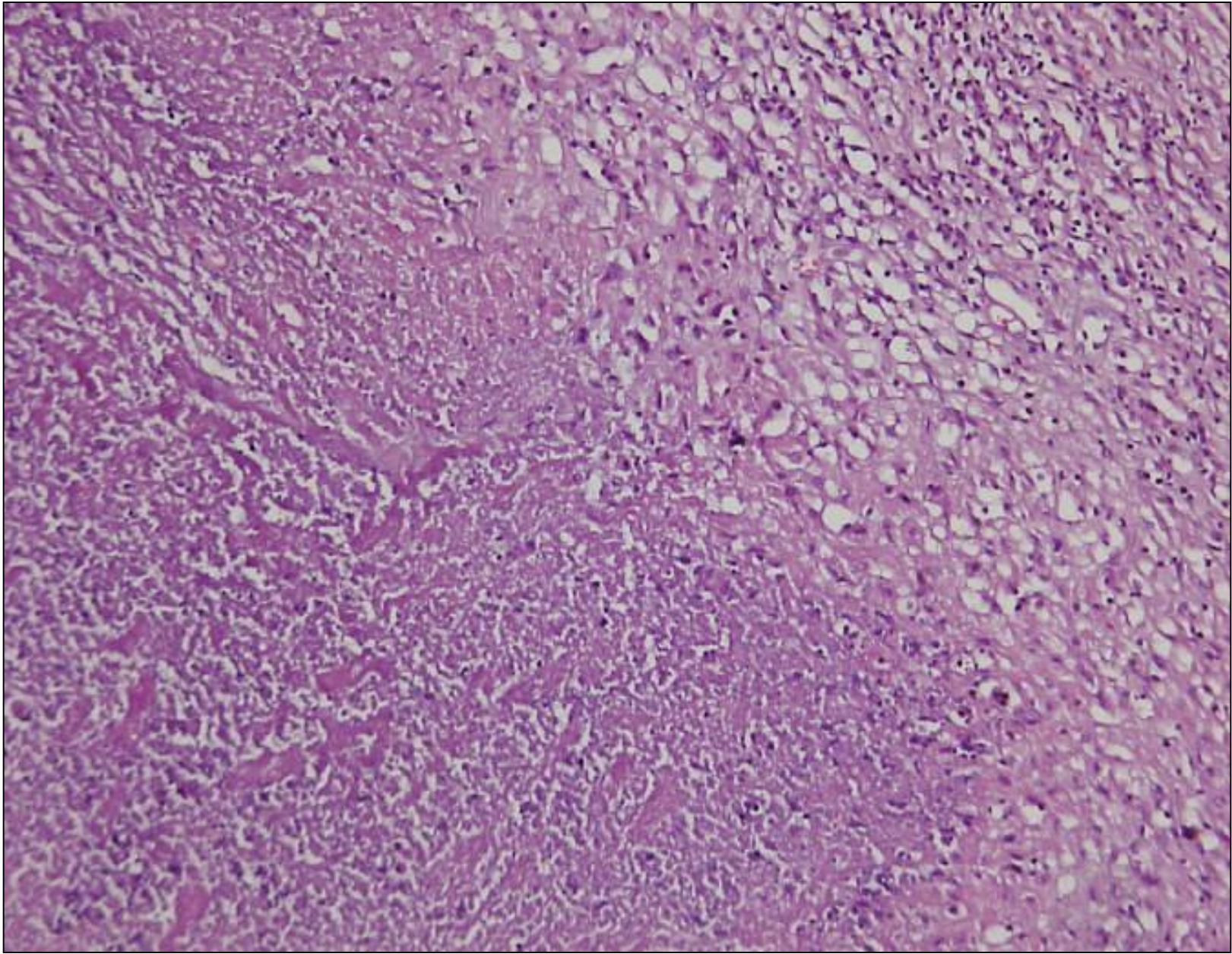
27 8:03 AM

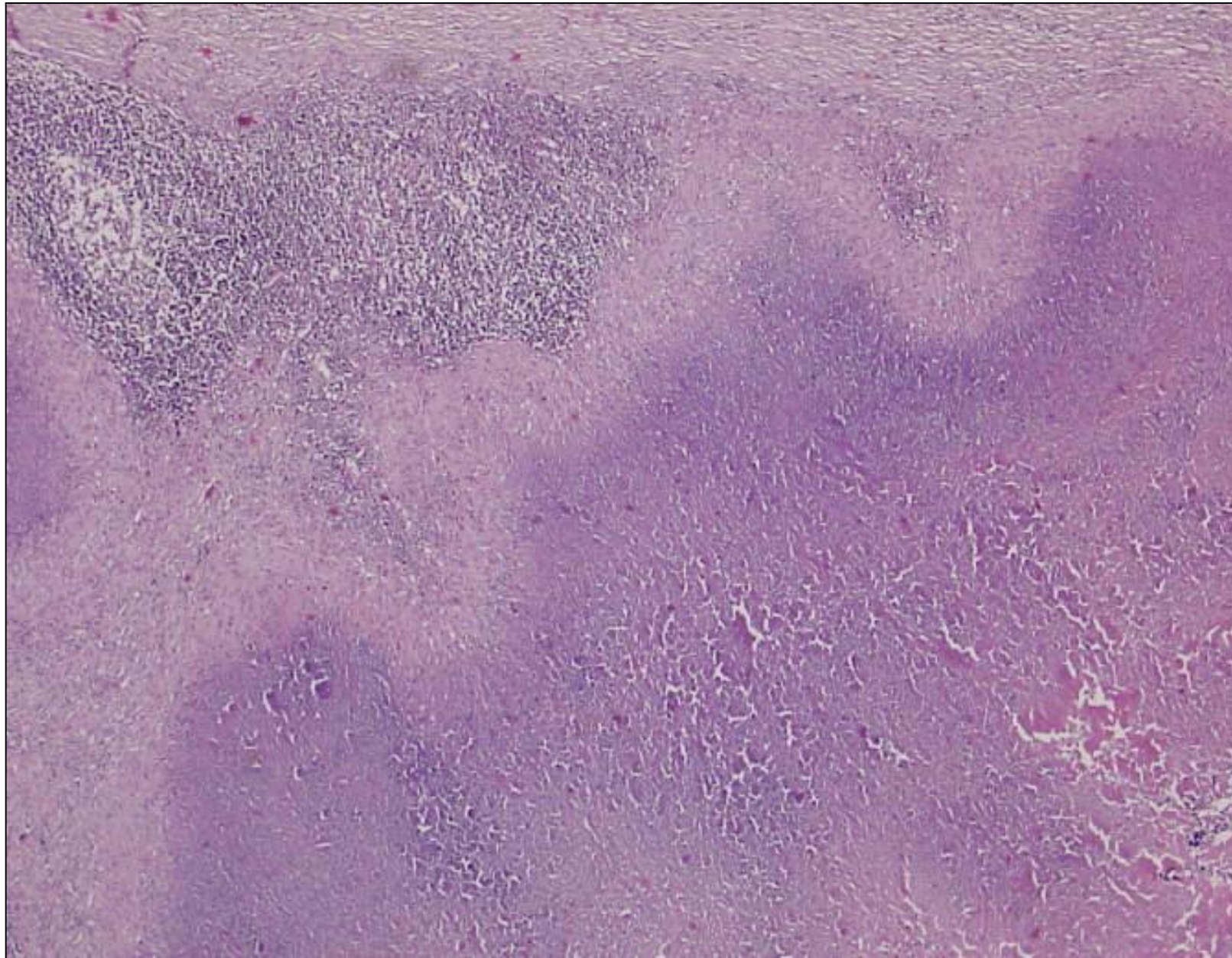


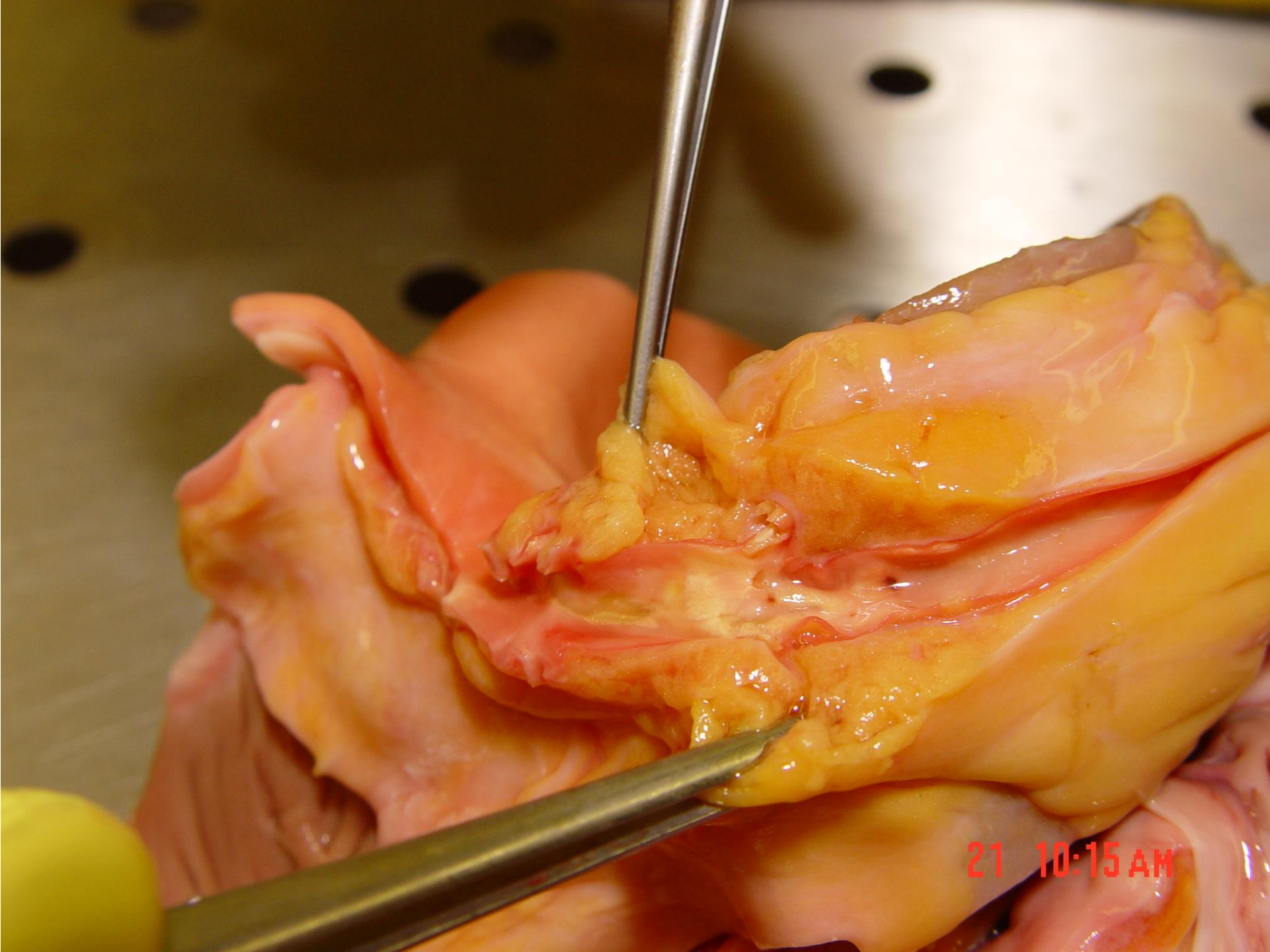
27 8:04 AM

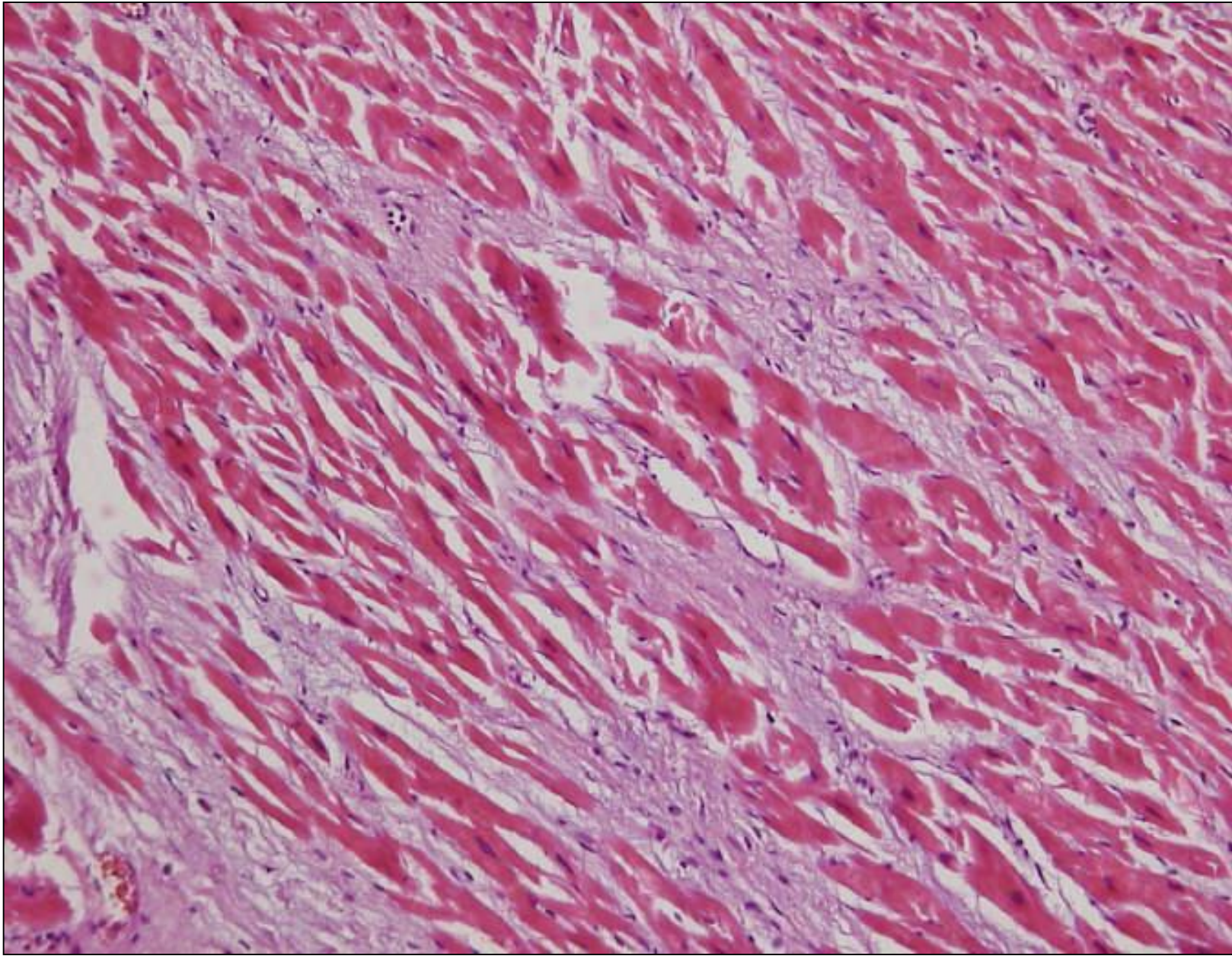


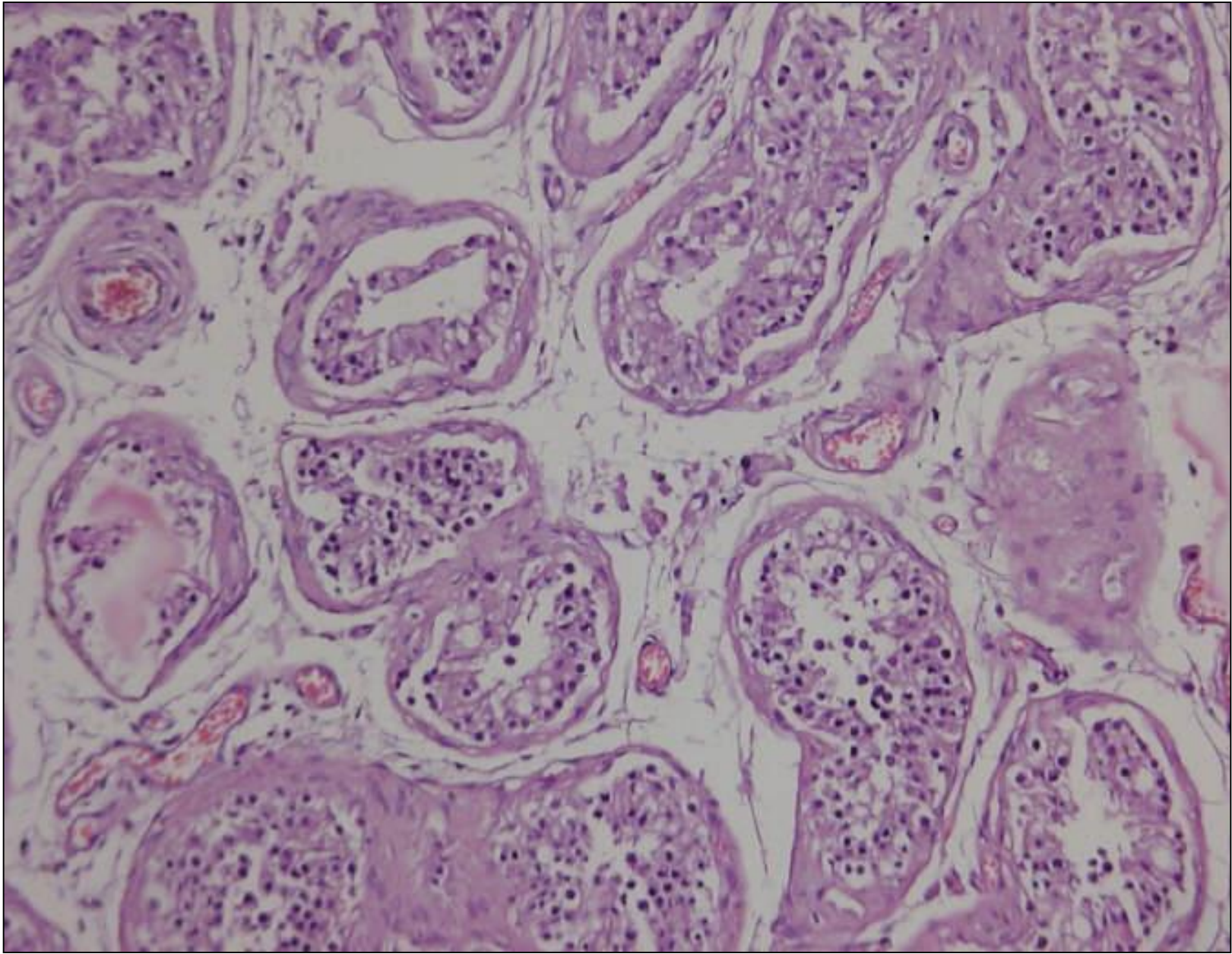


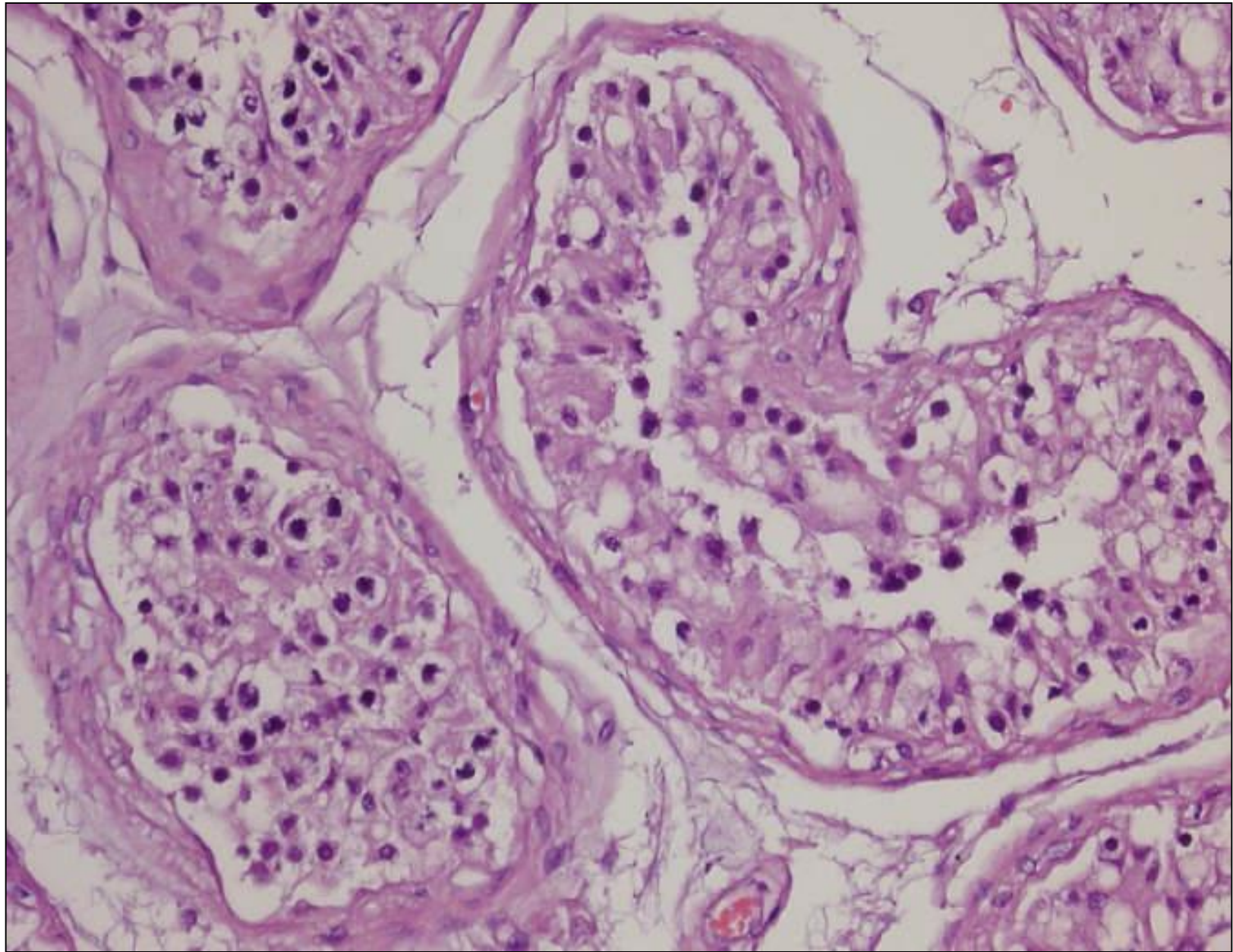


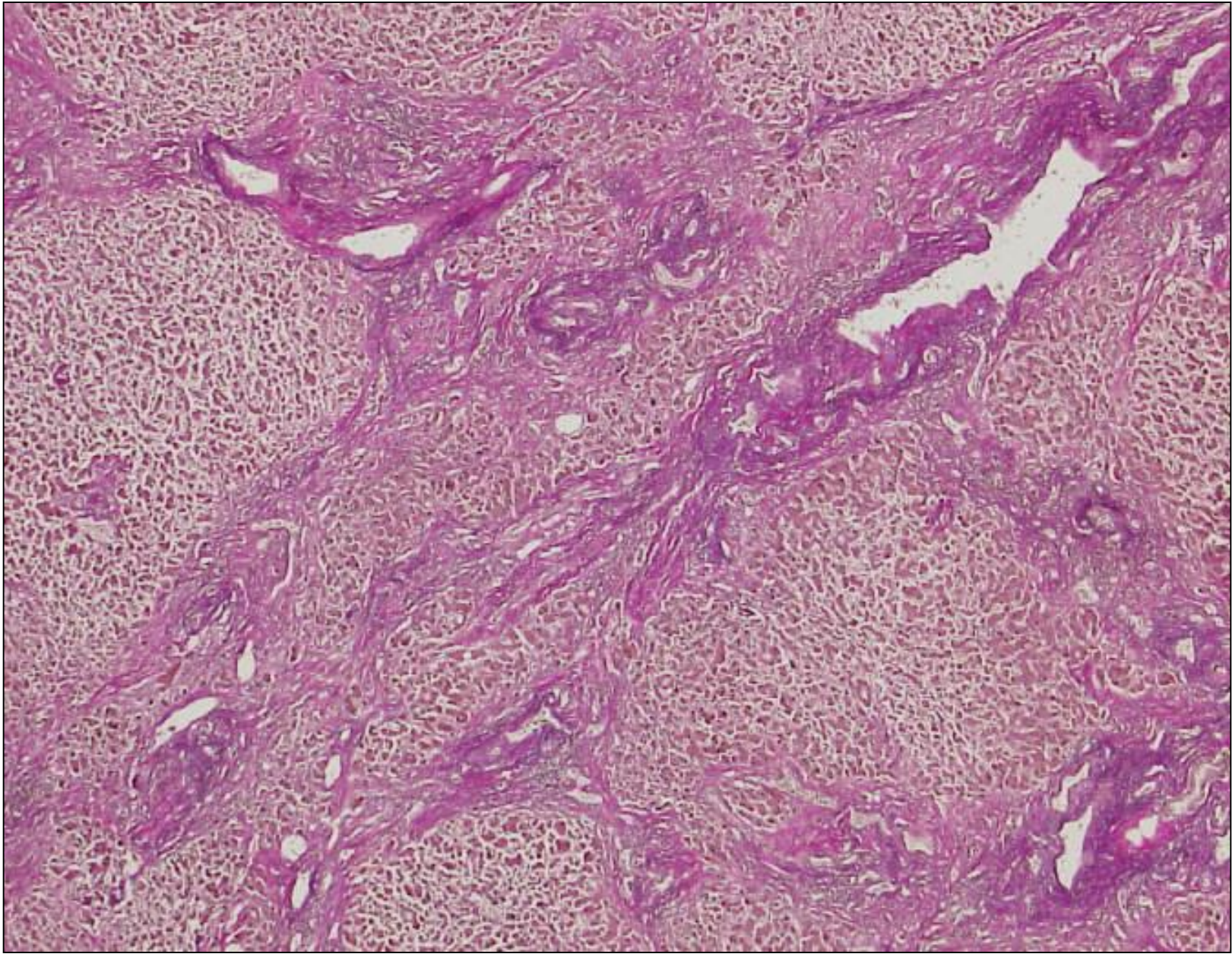


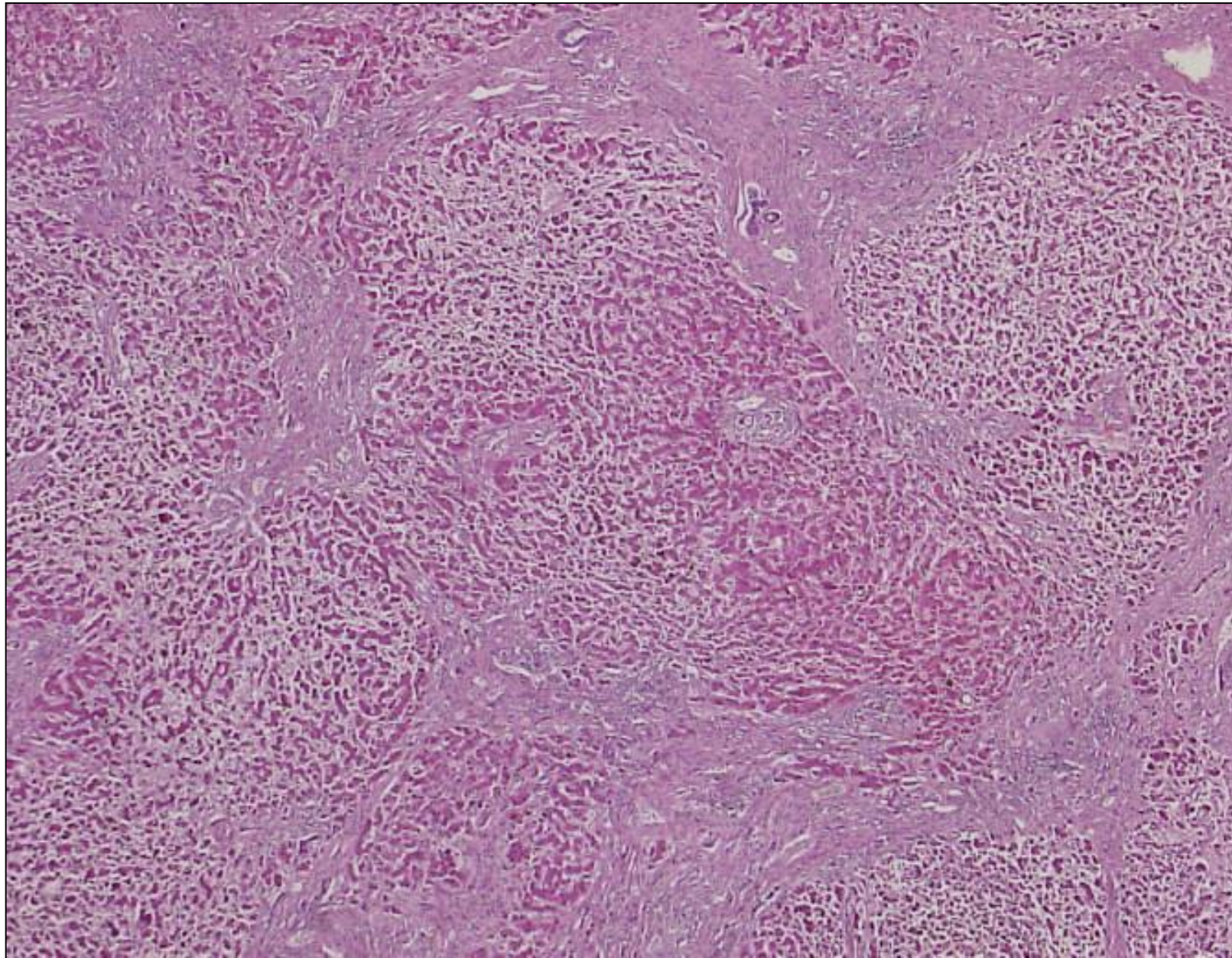


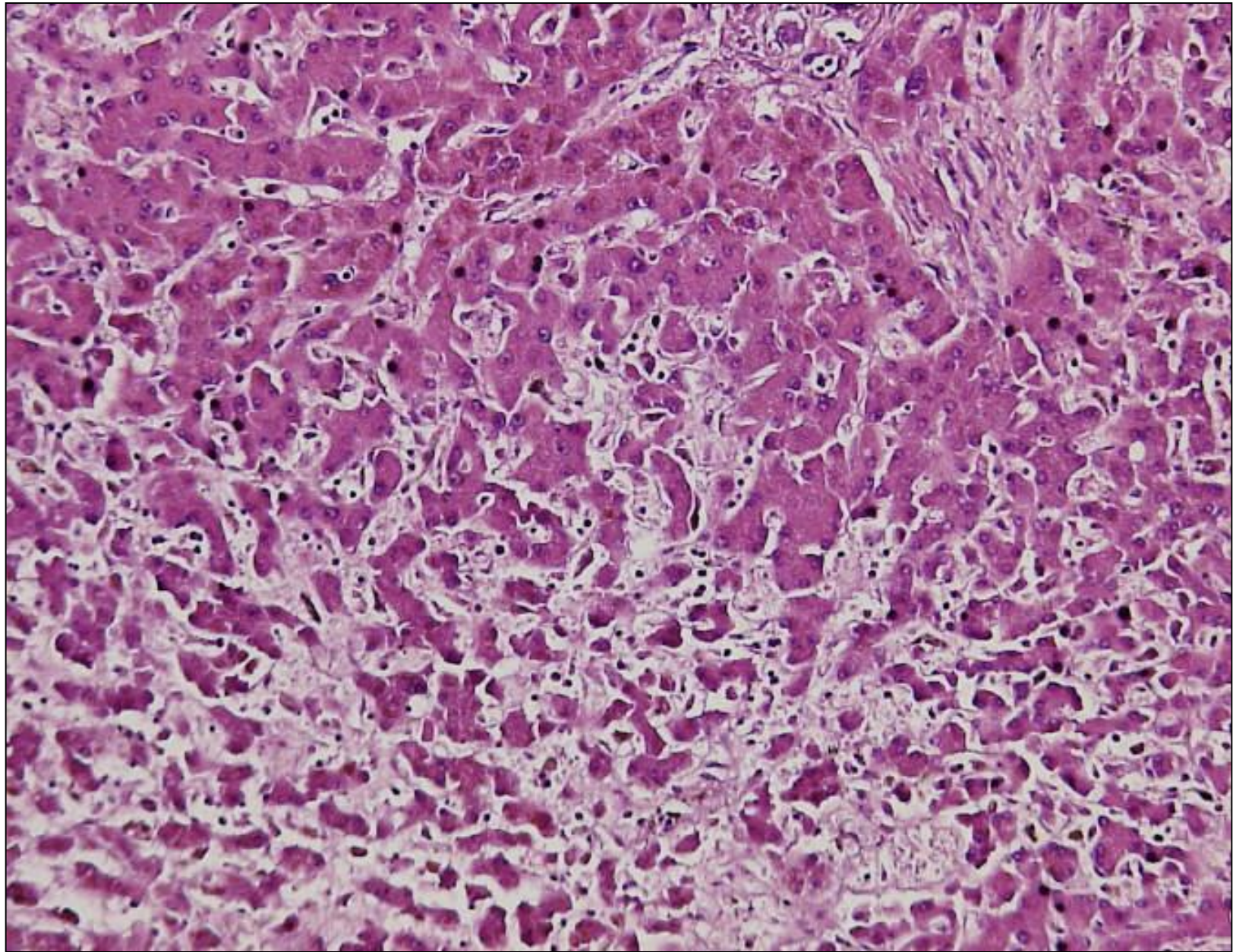


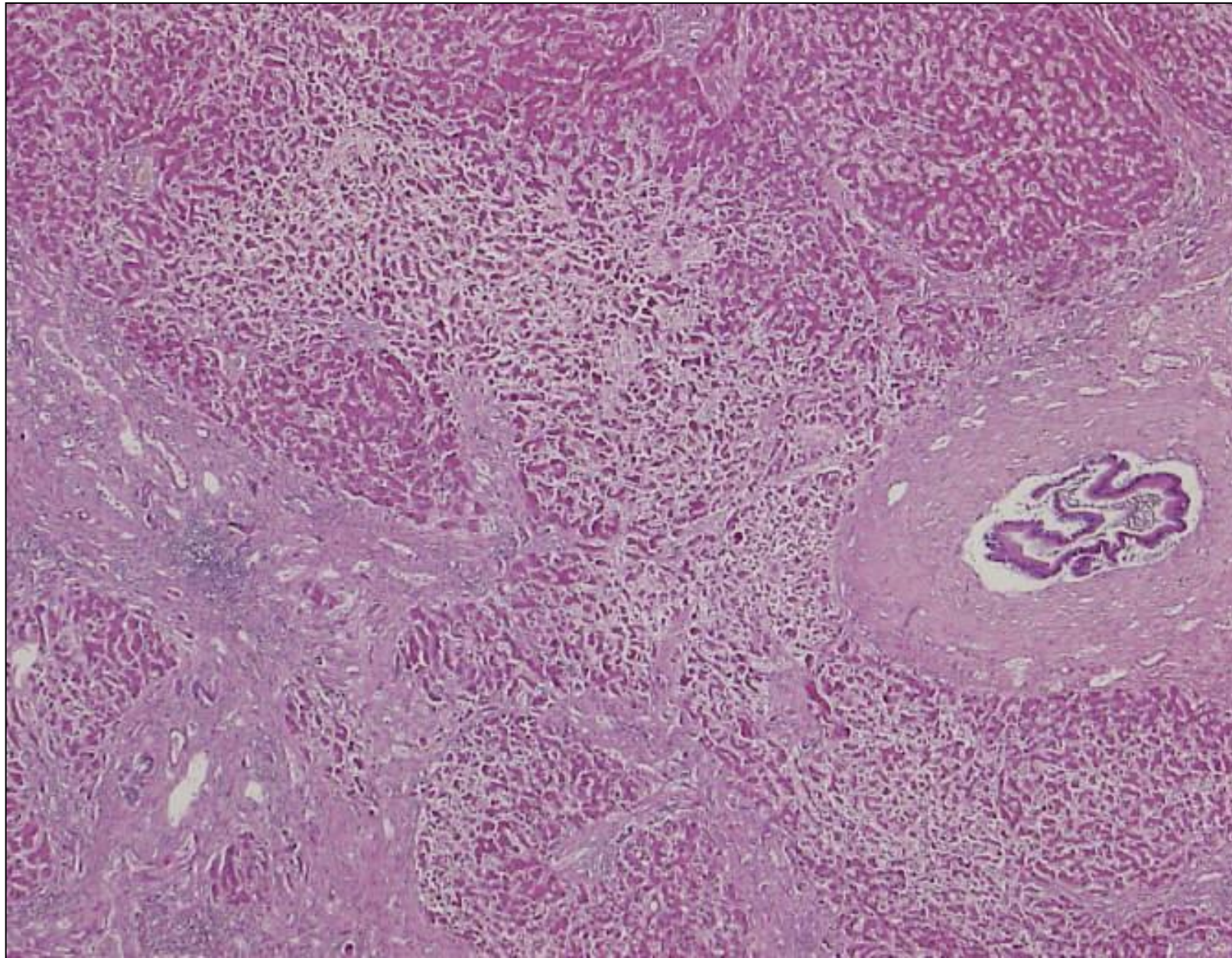


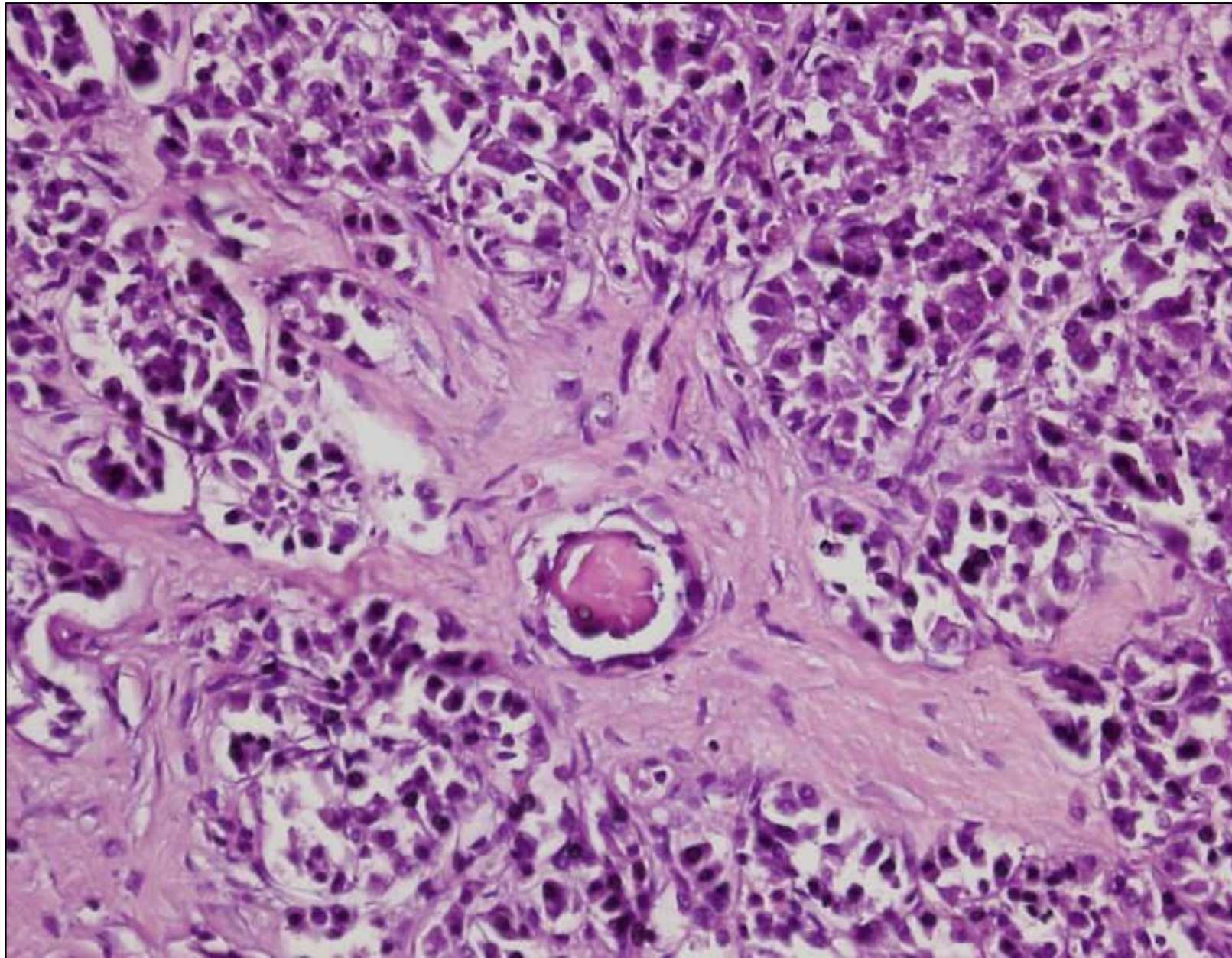


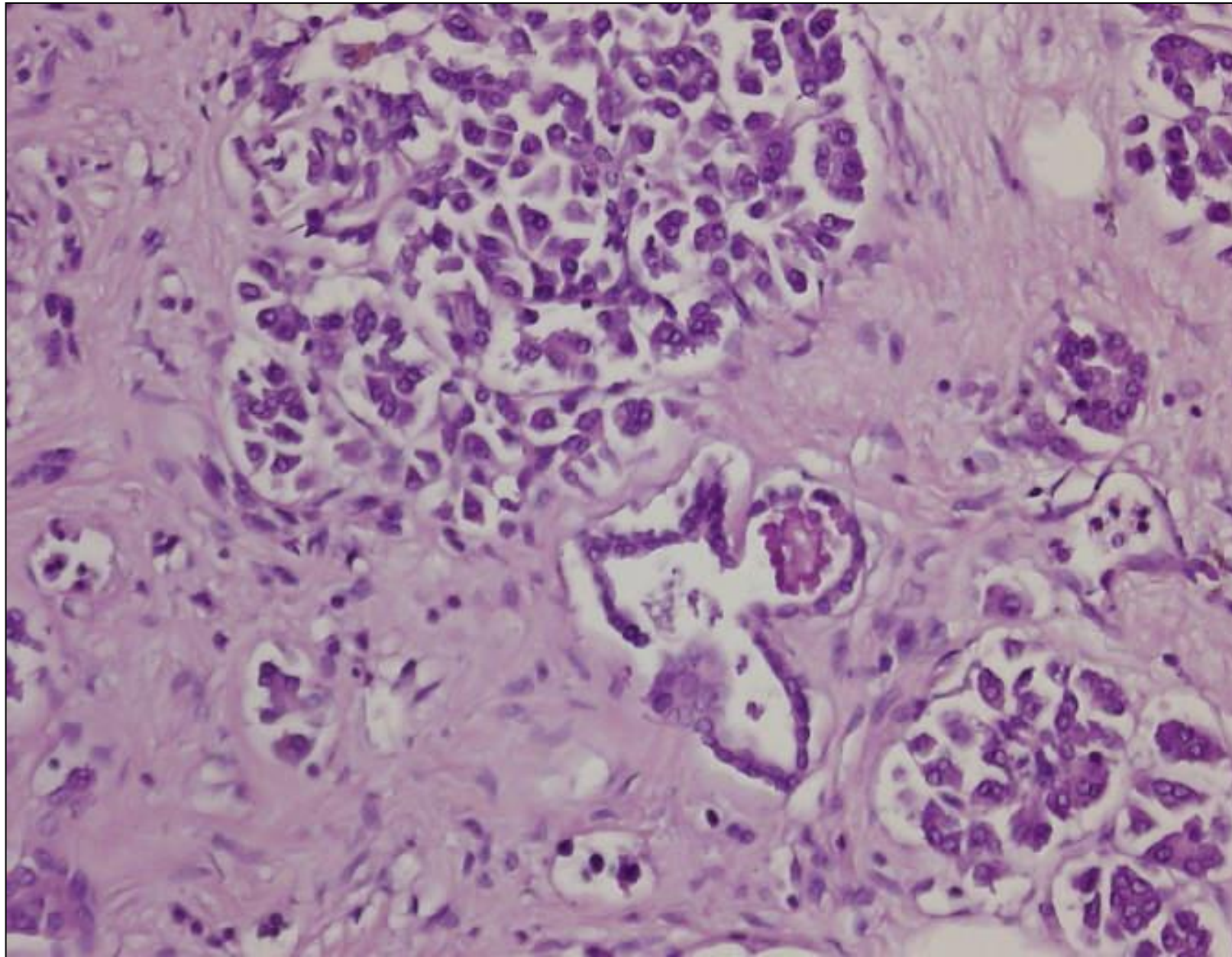


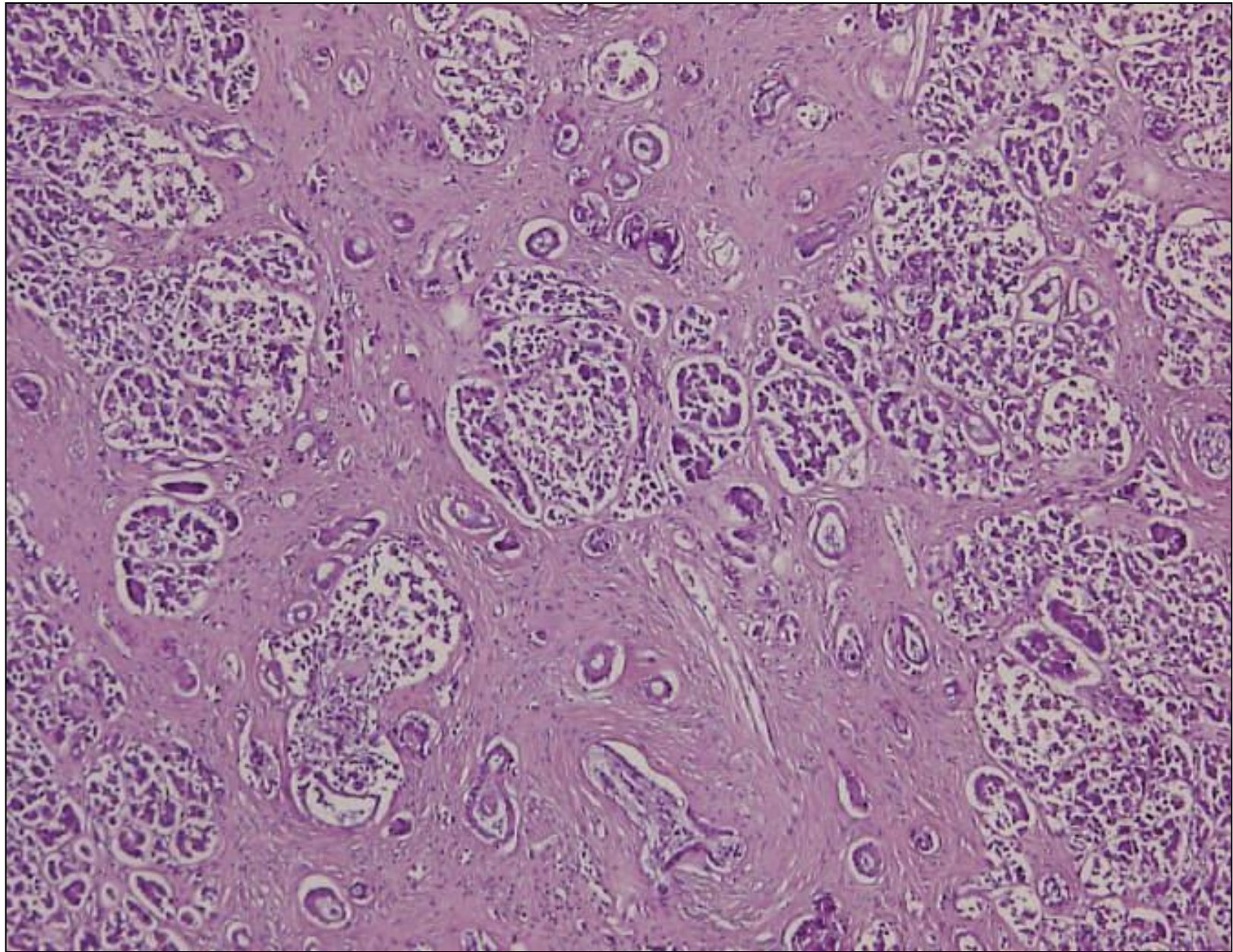


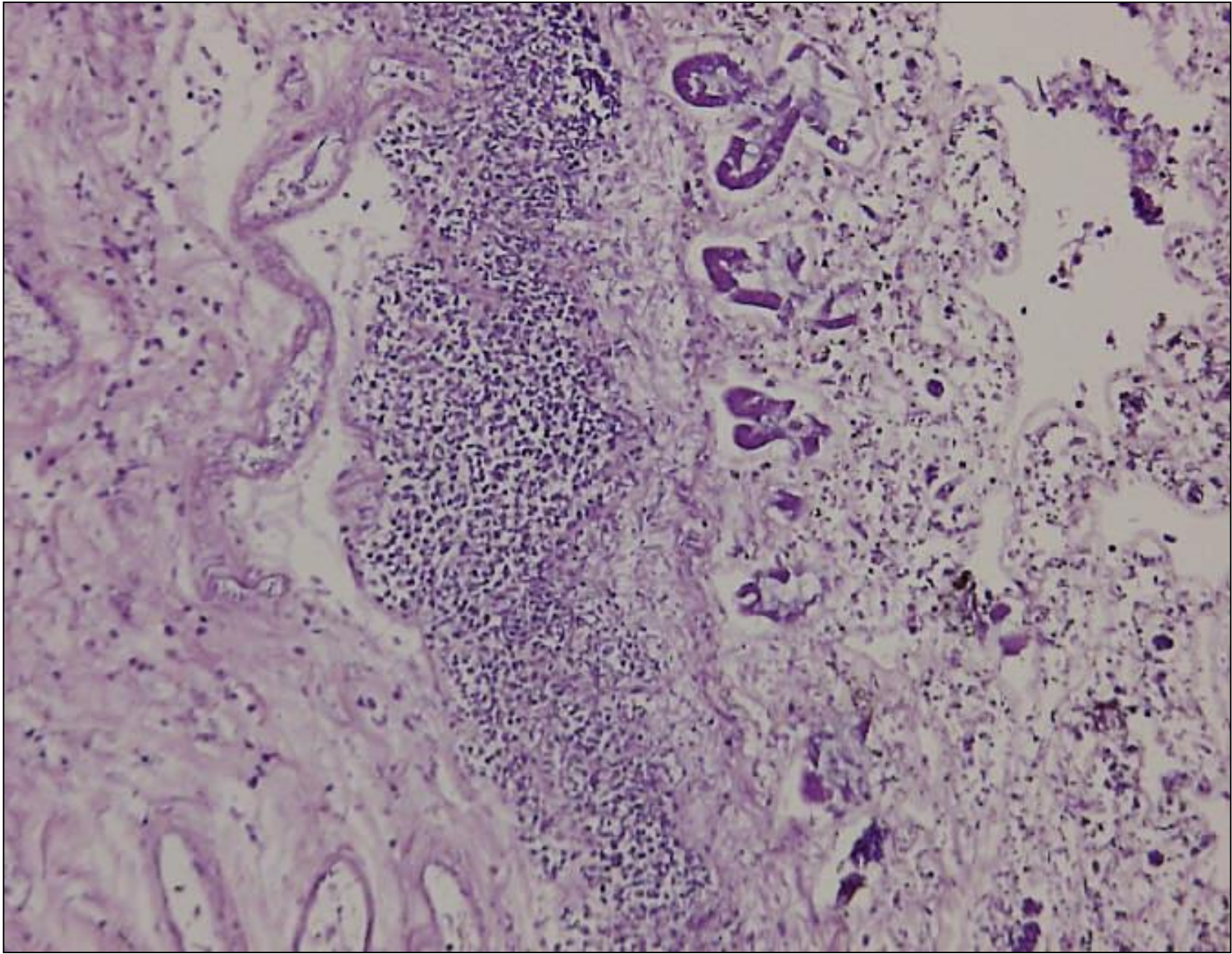


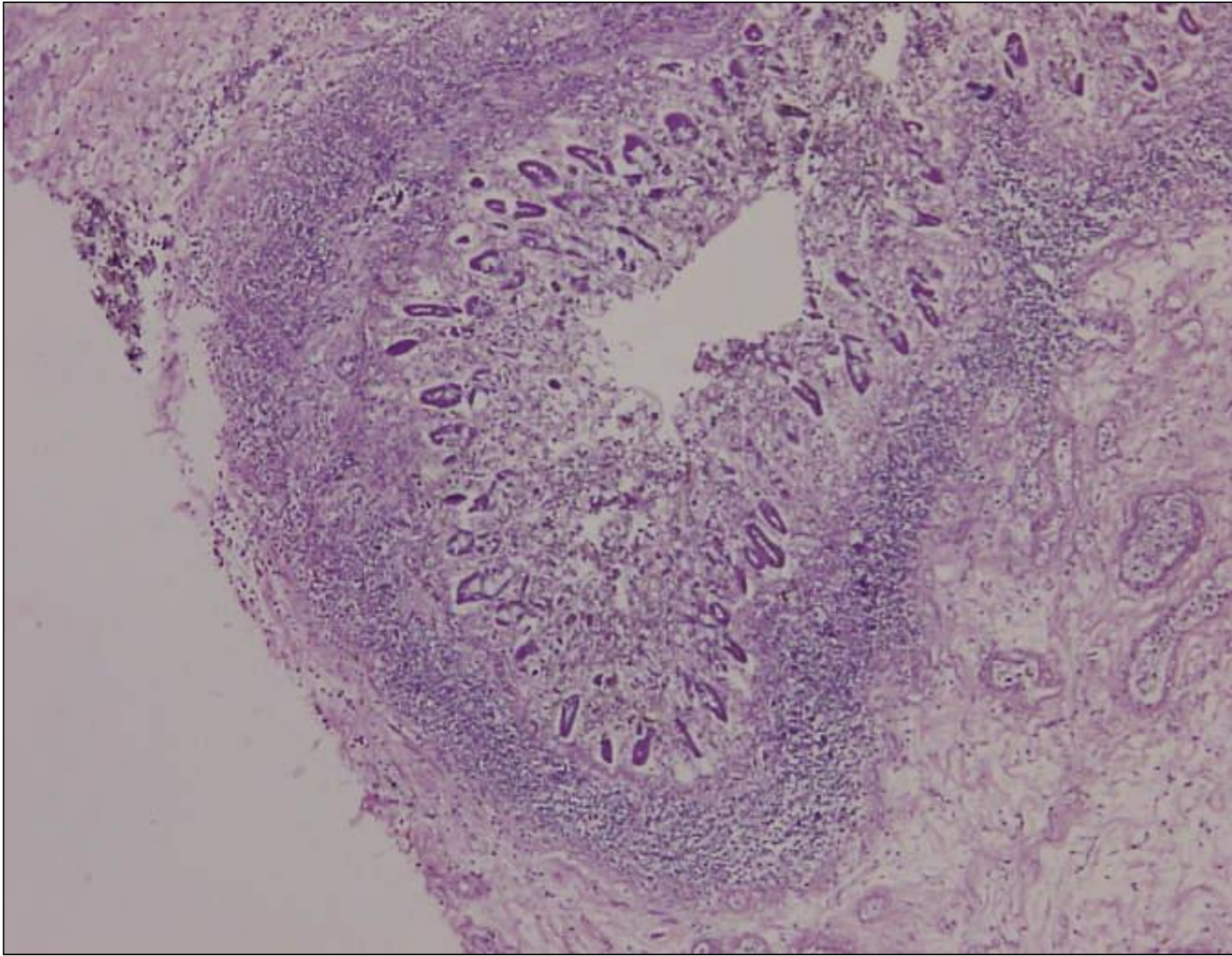


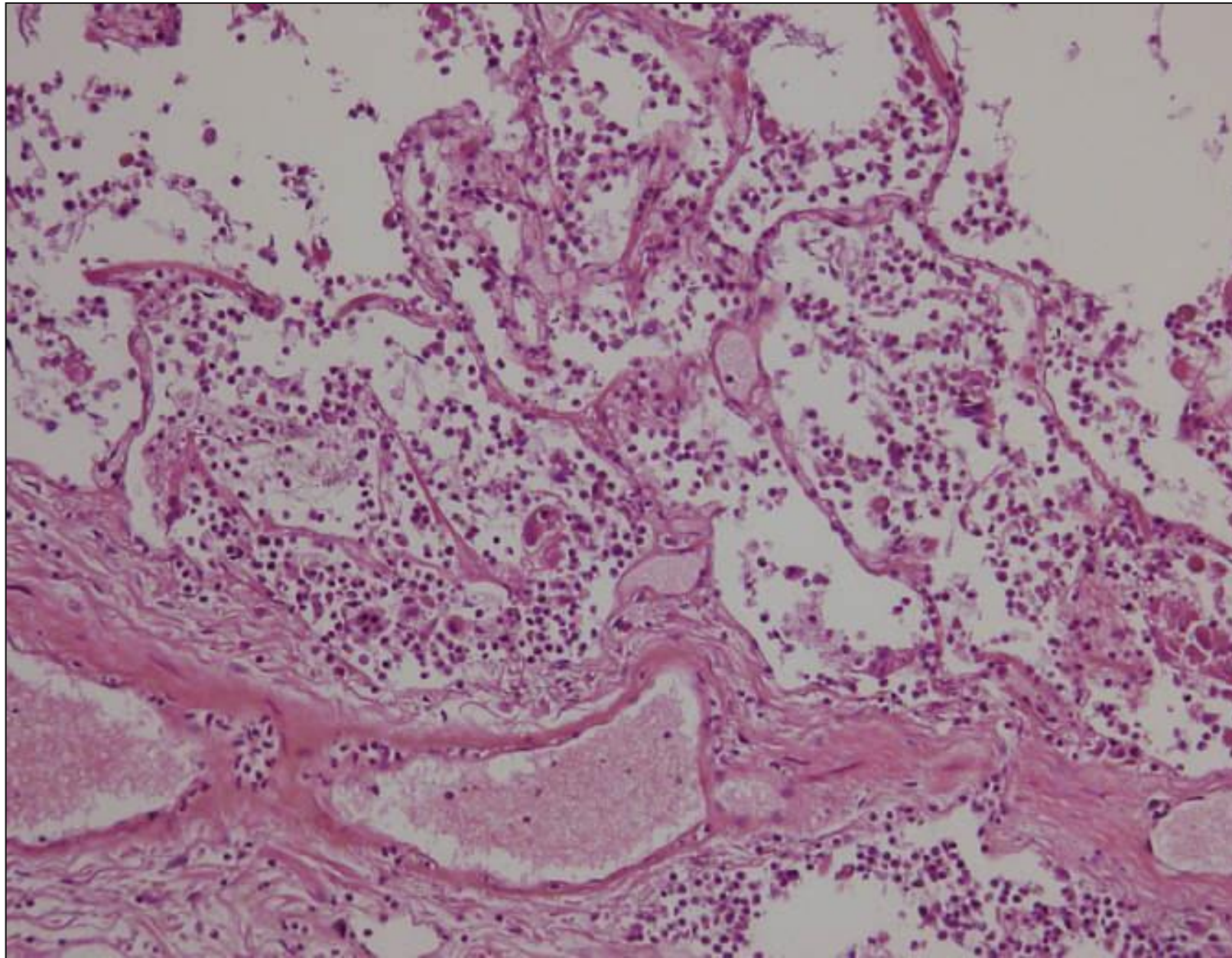


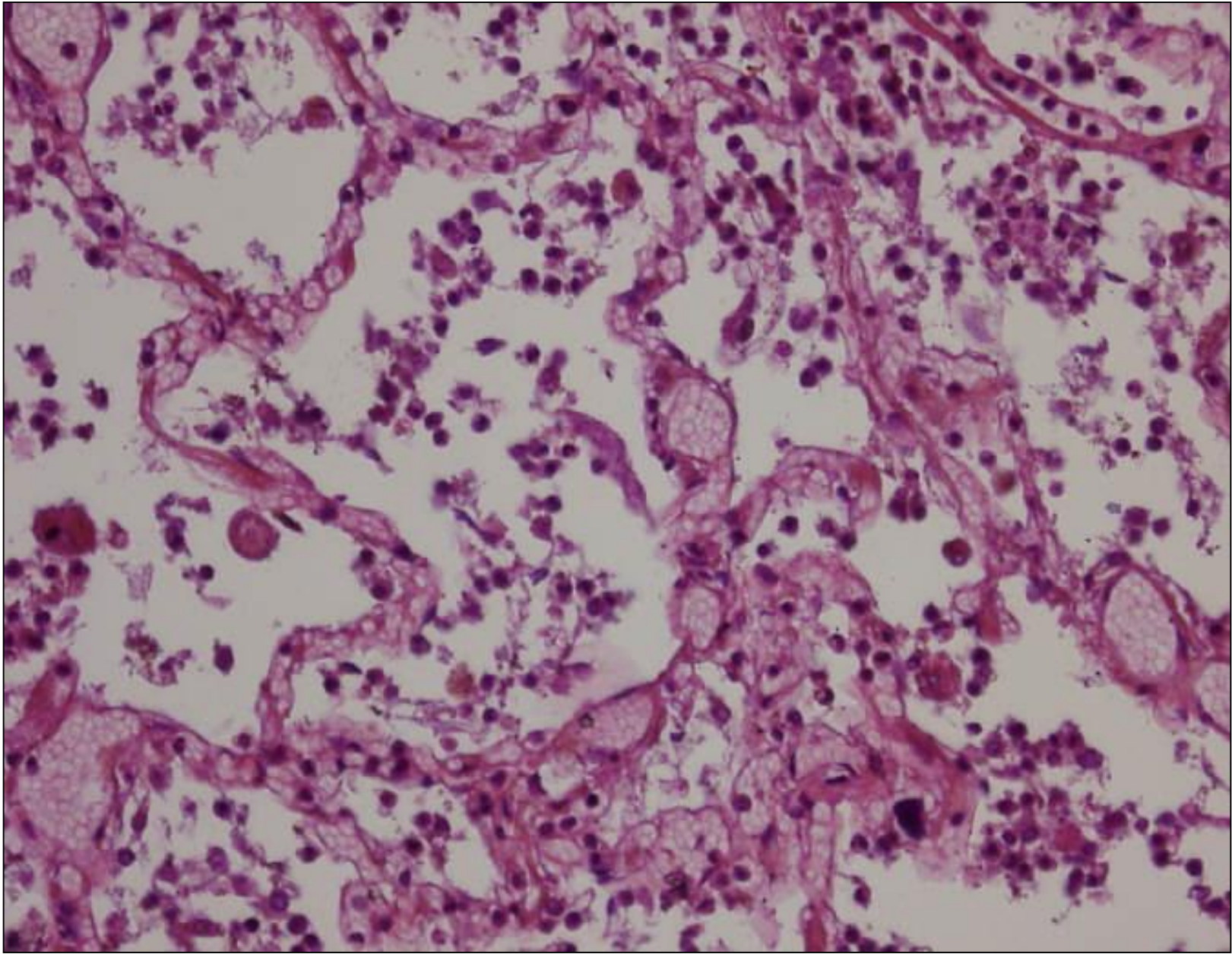


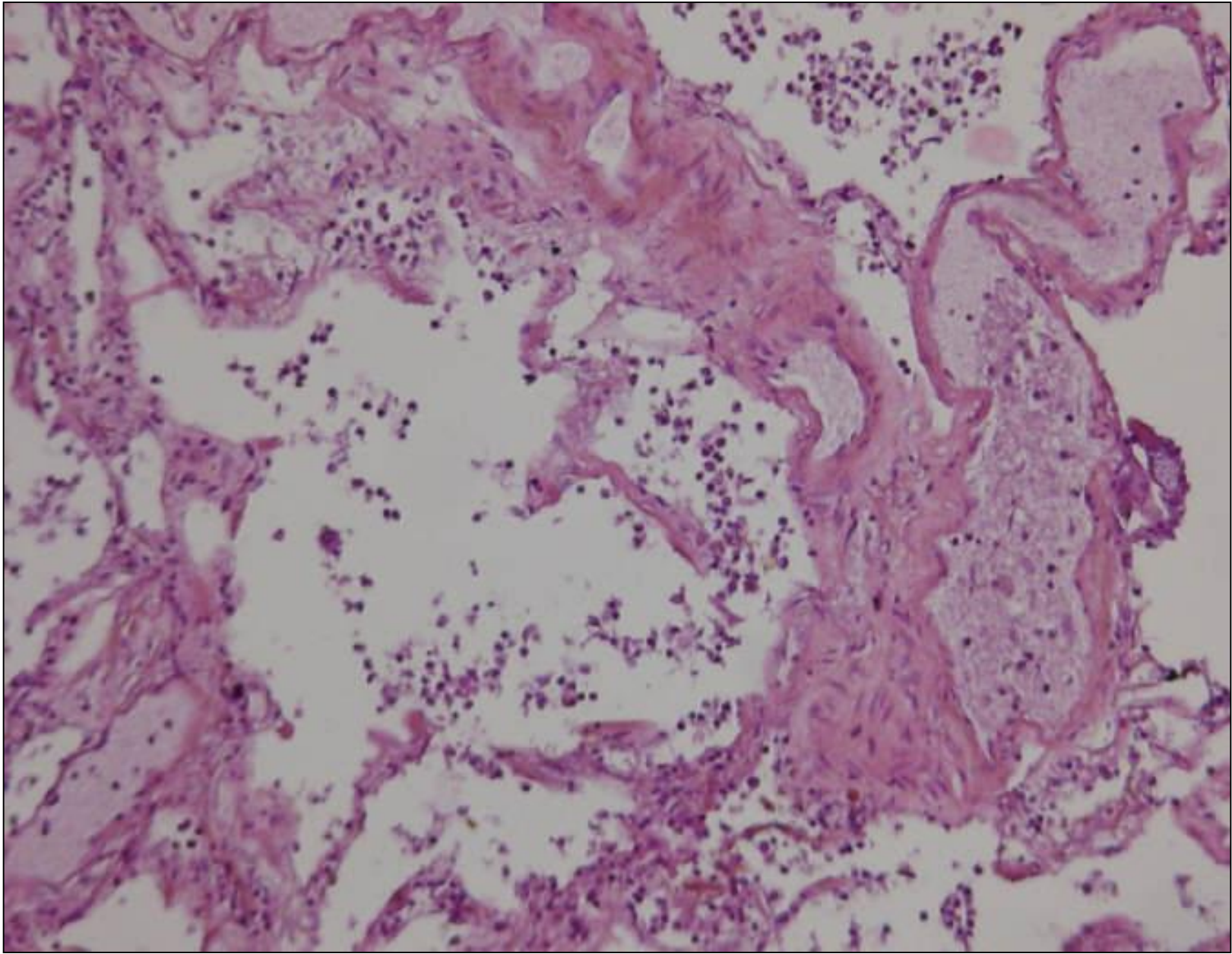


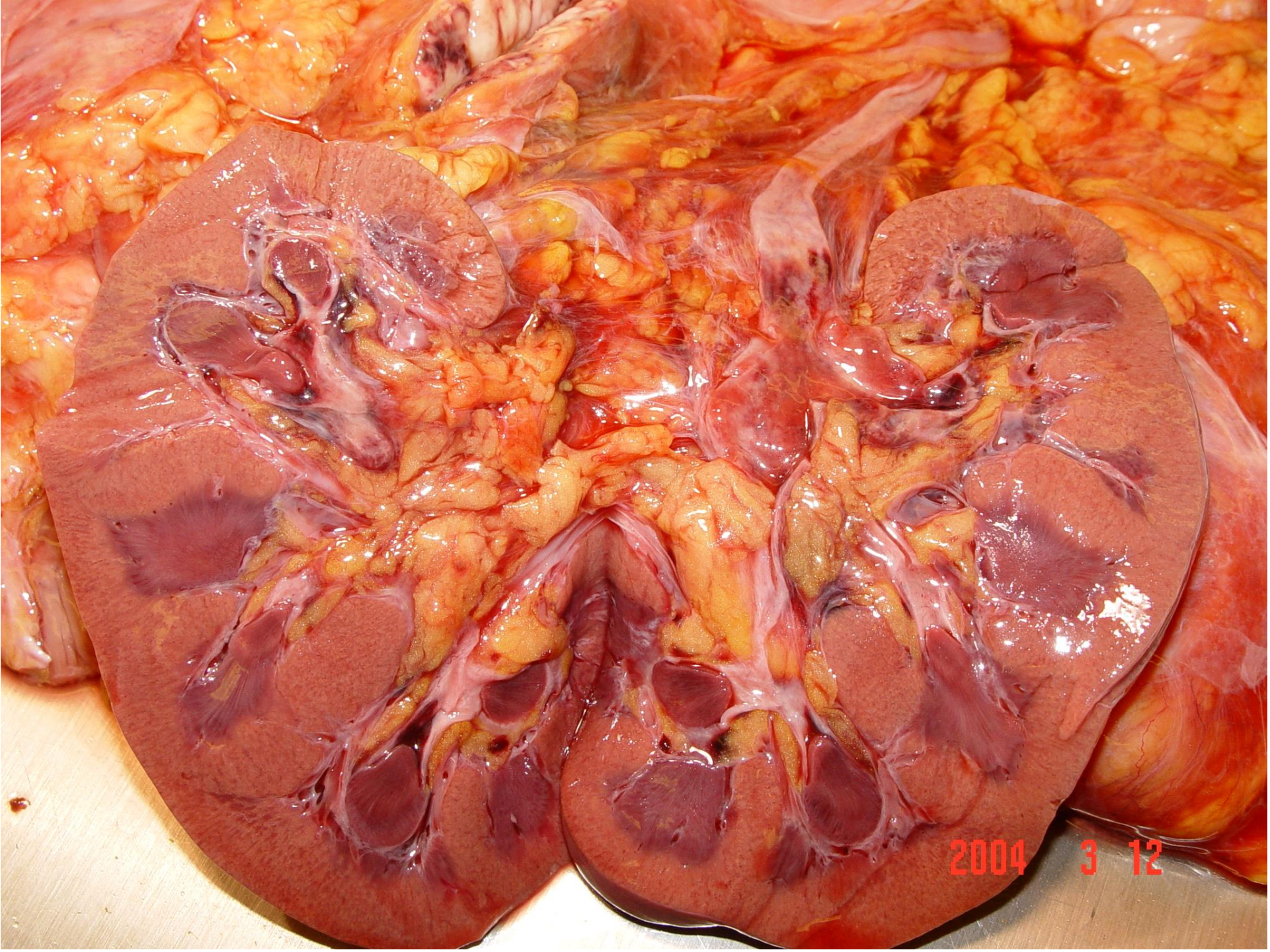












2004 3 12

